

Health adverse effects of formaldehyde exposure to students and staff in gross anatomy

Fahima A Alnagar¹, Mansur E Shmela², Abdulrhman M Alrtib³, Fathia M Benashour¹,
Amal O Buker³, Anwar M Abdalmula¹

¹Department of Physiology, Biochemistry and Nutrition, Faculty of Veterinary Medicine, University of Tripoli, Tripoli, Libya.

²Department of Preventive Medicine, Genetics & Animal Breeding, Faculty of Veterinary Medicine, University of Tripoli, Tripoli, Libya.

³Department of Anatomy, Histology and Embryology, Faculty of Veterinary Medicine, University of Tripoli, Tripoli, Libya.

Abstract:

Formaldehyde is an anxious gas used as a tissue preservative of cadavers in anatomy halls. Therefore, laboratory staff and students are at high risk of different clinical complications due to the continuous exposure to formaldehyde. The present questionnaire-based study evaluates the effects of formaldehyde exposure on veterinary students and staff in the anatomy gross dissection laboratory, University of Tripoli, Libya. A total of 104 students and 6 anatomy staff members completed a questionnaire of 24 questions related to the clinical symptoms observed after formaldehyde exposure and the answers were assessed using a six point (0-5) scale. Students had a high prevalence of nasal itching 78(75%), eyes burning 78(75%), excessive lacrimation 76(73%), eyes redness 60(58%), headache 64(62%) and respiratory distress 61(59%). Smoking and wearing glasses or gloves worsened many symptoms while wearing masks minimized other symptoms and male students were more affected than females. All anatomy staff members (100%) reported nasal itching, burning and congestion, eyes burning and redness, excessive lacrimation, cough and respiratory distress and less than that (83%) suffered from mouth dryness, headache, temporary loss of their ability to recognize the smell of formaldehyde and needed a physician assistance after the exposure to formaldehyde. The repeated exposure to formaldehyde in gross anatomy dissection has harmful effects on both students and staff member and finding alternative preservation methods, such as freezing, would be safer than using the formaldehyde.

Key Words: Cadaver, Embalming fluid, Formaldehyde, Gross anatomy dissection laboratory.

1.Introduction

Formaldehyde is an anxious, flammable, extremely soluble gas in water and commercially available as formalin containing 37% by weight or 40% by volume of formaldehyde gas in water [1]. Formalin is the commonest preservative used for embalming and is the main component of the embalming fluid which is usually made up of a different chemical compounds including fixatives, preservatives, germicides, buffers, wetting agents, anticoagulants and dyes [2]. The embalming fluid is usually infused via the femoral arteries or the internal carotid arteries

to prevent the denaturation of the cadavers by solidification of tissue proteins, disinfection and maintenance of the integrity of the anatomic relations [3, 4]. During an anatomy class, the evaporation of formalaldehyde from cadavers and

embalming fluid could adversely affect students and staff's health [5]. Medical students, staff, and technicians are regularly exposed to formaldehyde in gross anatomy dissection by different routs including inhalation [2], contact with skin [6, 7], or accidentally by splashes to eyes [8] or splashes and ingestion to the gastro-intestinal tract (GIT) [9].

Although formaldehyde is metabolized in the body to formic acid which is a non-toxic compound excreted in the urine or converted to carbon dioxide and excreted by the lungs [10], it can be allergenic [11], carcinogenic [12, 13] or toxic to many organs such as pancreas, liver, kidney and brain [14].

Many studies were conducted on medical students worldwide to explore the adverse effects of using formaldehyde in gross anatomy laboratories [4, 15-20]. These studies found that students and staff members suffered from many harmful effects caused

by the exposure to formaldehyde. Most of these effects could be avoided by using protective equipments and improving laboratory ventilation conditions which minimize the released amount of formaldehyde in the ambient air [21, 22]. In addition, some individuals were highly sensitive to the formaldehyde while others were more resistant and had no reaction to the same levels of exposure [11, 16].

The aim of the present study is to assess the adverse health effects of using formalin as cadavers' preservative in the gross anatomy dissection laboratory on the veterinary students and staff at the Department of anatomy, Faculty of Veterinary Medicine, University of Tripoli, Libya.

2. Materials and Methods

The study population of this questionnaire-based study included the undergraduate students and staff of the anatomy department. The objective of this study was explained to the participants and assurance was given that the information to be collected would be used for research purpose only. The questionnaire used in this study consisted of two sections; the first section was about the occupation, age, sex, weight, height, smoking, general health condition and wearing protective equipments, such as coats, gloves, masks and glasses, during laboratory sessions while the second section included 24 questions about the expected formaldehyde effects on eyes, nose, mouth, respiratory tract, GIT and skin. The participants were also asked to answer questions regarding sleeping disturbances, assimilation, and if they needed a physician assistant after they were exposed to the formaldehyde. Students with a history of respiratory, allergy or skin disorders were excluded from the study. The answers were assessed using a six point (0-5) scale (zero=no effect, 1=barely recognizable effect, 2=light effect, 3=moderate effect, 4=strong, prominent and irritating effect, and 5=intolerable effect) related to the symptoms developed following exposure to formaldehyde fixed cadavers.

Table 1: Symptoms prevalence among veterinary students exposed to formaldehyde in gross anatomy dissection laboratory

No	Symptoms	NO No(%)	YES No(%)					Total (1-5)
			1	2	3	4	5	
1	Nasal itching and burning	26(25)	9(9)	26(25))	20(19))	18(17)	5(5)	78(75)
2	Nasal congestion	46(44)	12(12)	18(17)	17(16)	8(8)	3(3)	58(56)

3. Data analysis

Results are expressed as mean \pm SEM. Data were analysed using GraphPad Prism statistical software (version 6.0b; GraphPad Software Inc, La Jolla, CA, USA). Analysis of data between groups was performed using Mann-Whitney test and statistical significance between groups was accepted at $p < 0.05$.

4. Results

All (104) students completed and returned the questionnaires with a response of 100%. This study included 47 males and 57 females. The average of age was 18–28 (19.7) and 18–26(18.8) years, height (152cm), and (124cm) and weight (69.6kg) and (45.7 kg) for males and females, respectively. The mean duration of formaldehyde exposure was 8 hours per week during the course lasting for 28 weeks. Moreover, 6 male staff members with age ranged 31–58(42) years; mean height (173.2cm) and mean weight (78Kg) completed the questionnaires. The staff members were exposed to formaldehyde 4–8 hours daily during their routine work.

None of the female students were pregnant neither smokers. On the other hand, 23(49%) male students were non smokers, 14(30%) were smokers and 6(13%) were ceased smokers (stopped smoking before conducting this study). In regards to using the protective equipments in practical sessions, all students 104(100%) used laboratory coats while 32(31%), 22(19%) and 13(13%) students used gloves, glasses and, masks respectively.

The clinical symptoms observed on veterinary students after formaldehyde exposure are shown in Table 1. The results show high prevalence of different responses to the formaldehyde vapor with total percentages of nasal itching 78(75%), nasal congestion 58(56%), eyes burning 78(75%), eyes redness 60(58%), excessive lacrimation 76(73%), respiratory distress 61(59%), headache 64(62%) and low assimilation during dissection with 52(50%).

)))			
3	Nasal sore or dryness	72(69)	7(7)	13(13)	7(7)	4(4)	1(1)	32(31)
4	Temporary loss of the ability to smell or to see after repeated exposure to formaldehyde	65(62)	13(13)	9(9)	9(9)	4(4)	4(4)	39(38)
5	The ability to recognize the smell of formaldehyde	67(64)	13(12)	8(8)	6(6)	4(4)	6(6)	37(36)
6	Burning eyes	26(25)	10(10)	15(14)	29(28)	19(18)	5(5)	78(75)
7	Redness of the eyes	44(42)	12(12)	17(16)	19(18)	11(11)	1(1)	60(58)
8	Itching or sore eyes	60(58)	13(13)	14(13)	13(13)	3(3)	1(1)	44(42)
9	Excessive lacrimation	28(27)	15(14)	21(20)	20(19)	14(13)	6(6)	76(73)
10	Dry mouth	61(59)	12(12)	19(18)	7(7)	4(4)	1(1)	43(41)
11	Unusual thirst	66(63)	9(9)	17(16)	6(6)	4(4)	2(2)	38(37)
12	Cough	56(54)	16(15)	10(10)	11(11)	9(9)	2(2)	48(46)
13	Sore throat or dryness	69(66)	14(13)	13(13)	5(5)	2(2)	1(1)	35(34)
14	Respiratory distress	43(41)	13(13)	17(16)	21(20)	5(5)	5(5)	61(59)
15	GIT disturbances	69(66)	10(10)	7(7)	9(9)	7(7)	2(2)	35(34)
16	Nausea	68(65)	13(13)	13(13)	3(3)	5(5)	2(2)	36(35)
17	Headache	40(38)	11(11)	14(13)	19(18)	14(13)	6(6)	64(62)
18	Disturbed sleep	65(62)	13(13)	5(5)	13(13)	5(5)	3(3)	39(38)
19	Prolonged sleeping time	64(62)	14(13)	5(5)	9(9)	10(10)	2(2)	40(38)
20	Unusual tiredness or dizziness	56(54)	19(18)	7(7)	14(13)	6(6)	2(2)	48(46)
21	Low assimilation	52(50)	19(18)	7(7)	11(11)	10(10)	5(5)	52(50)
22	Syncope (fainting episode)	95(91)	4(4)	1(1)	0(0)	2(2)	2(2)	9(9)
23	Itching or sore skin	73(70)	10(10)	9(9)	5(5)	3(3)	4(4)	31(30)
24	The need for a physician assistance after exposure to formaldehyde	89(86)	-	-	-	-	-	15(14)

The correlation between several parameters used in this study and adverse effects of formaldehyde was investigated and showed in figures 1-5. Figure 1 shows a significant correlation between different

smoking categories [non-smokers, continued smokers, ceased smokers and aggregate smokers (continued smokers and ceased smokers)] and some observed clinical symptoms. Smokers had more

excessive lacrimation ($P=0.0468$), prolonged sleeping ($P=0.0068$), unusual thirst ($P=0.0149$), mouth dryness ($P=0.0014$), nasal sore or dryness ($P=0.0189$), low assimilation ($P=0.0119$) and GIT disturbances ($P=0.037$) than none smokers. Moreover, students who ceased smoking had more

prolonged sleeping time ($P=0.011$), mouth dryness ($P=0.012$), and GIT disturbances ($P=0.0076$) than none smokers while students who were continued smokers showed more unusual thirst ($P=0.0366$) and mouth dryness ($P=0.0150$) than nonsmokers.

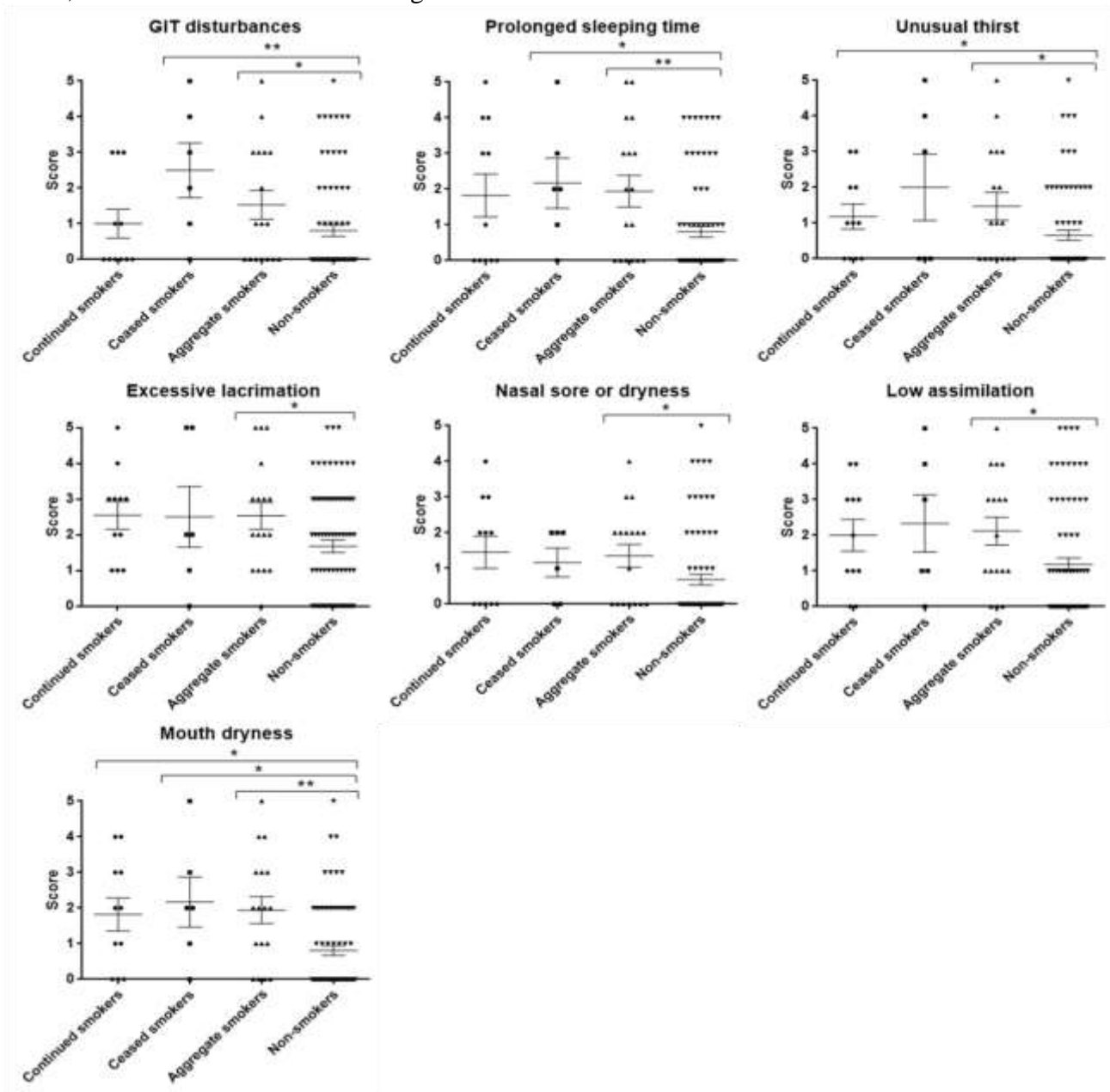


Fig.1. Formaldehyde association with smoking. The relationship between formaldehyde and smoking was scored based on the following criteria: 0 = no effect, 1 = barely recognizable, 2 = light, 3 = moderate, 4 = strong, prominent and irritating and 5 = intolerable. Values are expressed as mean \pm SEM of 11 smokers, 6 ceased smokers and 77 non-smokers and were compared using Mann–Whitney tests with *and ** representing $p \leq 0.05$ and 0.01 respectively.

Significant correlation was also found between wearing masks, glasses and gloves and the clinical symptoms developed during or after the laboratory courses. Figure 2 shows students who do not wear

masks suffered from more prolonged sleeping ($P=0.0487$), unusual thirst ($P=0.0441$), respiratory distress ($P=0.0356$) and sore throat or dryness ($P=0.0370$) than those who wear it.

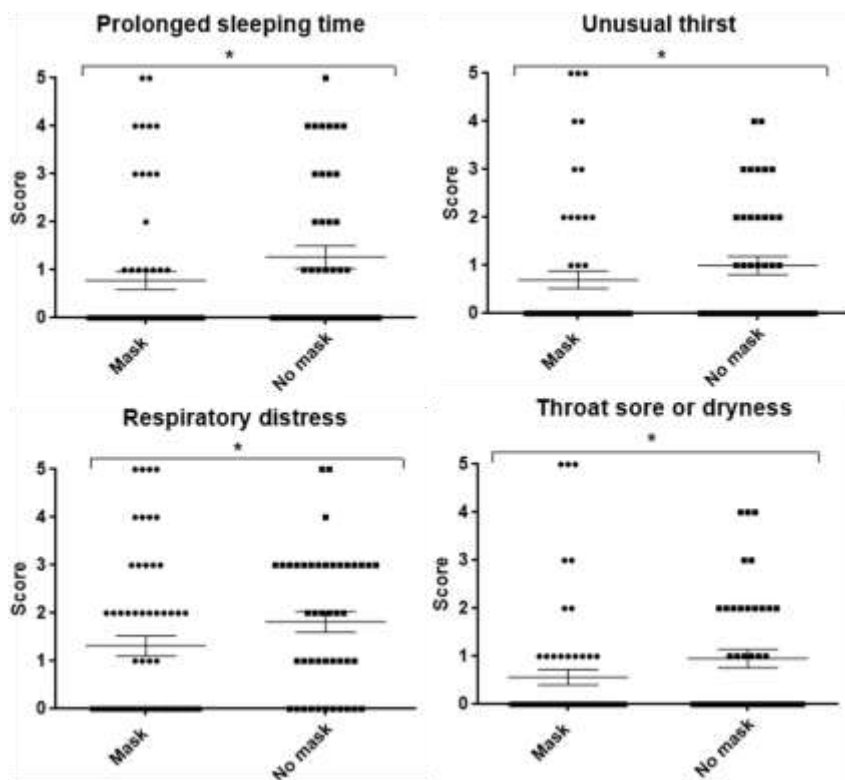


Fig.2. Formaldehyde association with mask wearing. The relationship between formaldehyde and wearing of masks was scored based on the following criteria: 0 = no effect, 1 = barely recognizable, 2 = light, 3 = moderate, 4 = strong, prominent and irritating and 5 = intolerable. Values are expressed as mean \pm SEM of 60 mask wearing students and 44 non-mask wearing students and were compared using Mann–Whitney tests with * representing $p \leq 0.05$.

Figures 3 and 4 show that wearing glasses and gloves had more unpleasant effects on students than not wearing them. Wearing glasses caused itching or sore eyes ($P=0.0500$) while wearing gloves resulted

in headache ($P=0.0176$) and temporary loss of smelling or vision ability after formaldehyde exposure ($P=0.0264$).

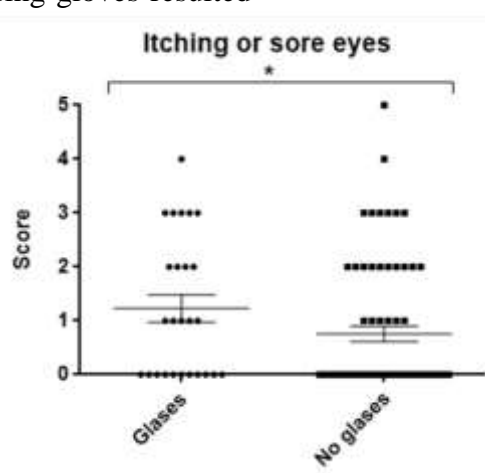


Fig.3. Formaldehyde association with glasses wearing. The relationship between formaldehyde and glasses wearing was scored based on the following criteria: 0 = no effect, 1 = barely recognizable, 2 = light, 3 = moderate, 4 = strong, prominent and irritating and 5 = intolerable. Values are expressed as mean \pm SEM of 26 glasses wearing students and 80 non-glasses wearing students and were compared using Mann–Whitney tests with * representing $p \leq 0.05$.

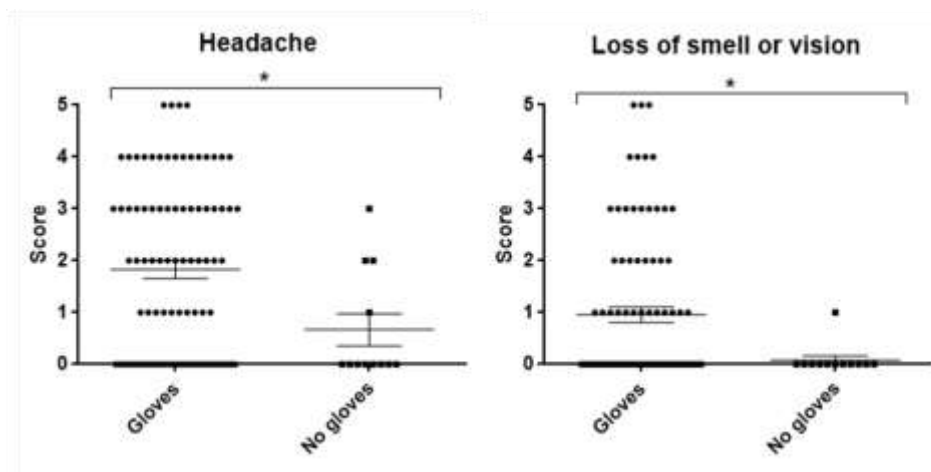


Fig.4. Formaldehyde association with gloves wearing. The relationship between formaldehyde and gloves wearing was scored based on the following criteria: 0 = no effect, 1 = barely recognizable, 2 = light, 3 = moderate, 4 = strong, prominent and irritating and 5 = intolerable. Values are expressed as mean \pm SEM of 91 gloves wearing students and 12 non-gloves wearing students and were compared using Mann–Whitney tests with * representing $p \leq 0.05$.

The gender effect was also investigated and is shown in Figure 5, where male students were more GIT disturbed than females ($P= 0.0430$).

Table 2, shows that all of the six (100%) staff members had nasal itching, burning and congestion, eyes burning and redness, excessive lacrimation, cough and respiratory distress. Five (83%) of staff members suffered from mouth dryness, headache,

loss of their ability to recognize the smell of formaldehyde and needed a physician assistance due to repeated exposure to formaldehyde. Four (67%) of staff members suffered from itching or sore skin and half of staff members 3(50%) suffered from unusual thirst and unusual tiredness after repeated exposure to formaldehyde.




Fig.5. Formaldehyde association with gender. The relationship between formaldehyde and gender was scored based on the following criteria: 0 = no effect, 1 = barely recognizable, 2 = light, 3 = moderate, 4 = strong, prominent and irritating and 5 = intolerable. Values are expressed as mean \pm SEM of 47 males and 57 females and were compared using Mann–Whitney tests with * representing $p \leq 0.05$.

Table 2: Symptoms prevalence among staff members exposed to formaldehyde in gross anatomy dissection laboratory.

No	Symptoms	NO No(%)	YES No(%)					Total (1-5)
			1	2	3	4	5	
1	Nasal itching and burning	0(0)	0(0)	0(0)	1(17))	5(83)	0(0)	6(100)
2	Nasal congestion	0(0)	0(0)	0(0)	3(50))	3(50)	0(0)	6(100)
3	Nasal sore or dryness	5(83)	0(0)	0(0)	1(17))	0(0)	0(0)	1(17)
4	Temporary loss of the ability to smell or to see after repeated exposure to formaldehyde	2(33)	1(17)	2(33)	0(0)	1(17)	0(0)	4(67)
5	The ability to recognize the smell of formaldehyde	1(17)	2(33)	3(50)	0(0)	0(0)	0(0)	5(83)
6	Burning eyes	0(0)	0(0)	3(34)	2(33))	2(33)	0(0)	6(100)
7	Redness of the eyes	0(0)	2(33)	1(17)	3(50))	0(0)	0(0)	6(100)
8	Itching or sore eyes	3(50)	1(16)	0(0)	1(17))	1(17)	0(0)	3(50)
9	Excessive lacrimation	0(0)	1(16)	1(17)	3(50))	1(17)	0(0)	6(100)
10	Dry mouth	1(16)	1(17)	1(17)	2(33))	1(17)	0(0)	5(84)
11	Unusual thirst	3(50)	1(17)	1(16)	1(17))	0(0)	0(0)	3(50)
12	Cough	0(0)	3(50)	2(33)	1(17))	0(0)	0(0)	6(100)
13	Sore throat or dryness	4(67)	0(0)	2(33)	0(0)	0(0)	0(0)	2(33)
14	Respiratory distress	0(0)	3(50)	1(17)	2(33))	0(0)	0(0)	6(100)
15	GIT disturbances	5(83)	0(0)	0(0)	1(17))	0(0)	0(0)	1(17)
16	Nausea	4(67)	2(33)	0(0)	0(0)	0(0)	0(0)	2(33)
17	Headache	1(17)	2(33)	2(33)	0(0)	1(17)	0(0)	5(83)
18	Disturbed sleep	4(67)	1(17)	0(0)	1(16))	0(0)	0(0)	2(33)
19	Prolonged sleeping time	4(67)	1(17)	0(0)	1(16))	0(0)	0(0)	2(33)
20	Unusual tiredness or dizziness	3(50)	0(0)	0(0)	3(50))	0(0)	0(0)	3(50)
21	Low assimilation	5(83)	0(0)	1(17)	0(0)	0(0)	0(0)	1(17)
22	Syncope (fainting episode)	6(100)	0(0)	0(0)	0(0)	0(0)	0(0)	0(0)
23	Itching or sore skin	2(33)	0(0)	1(17)	1(17))	2(33)	0(0)	4(67)
24	The need for a physician assistance after exposure to formaldehyde	1(17)	-	-	-	-	-	5(83)

5. Discussion

In veterinary medicine, gross anatomy is a fundamental subject describes the normal structures of different kinds of animal bodies. Formaldehyde is used as a cadaver antiseptic and fixative in anatomy dissection laboratory courses. It is emitted from the cadavers during gross anatomy dissection and may cause several toxic effects which adversely affect the health of students and staff members [16, 17, 19, 23]. In this study, we have reported that students and staff experienced various clinical symptoms after they repeatedly exposed to formaldehyde. Most of the students and staff members were interested in finding out about the effects of formaldehyde on their health, positively responded by returning the filled questionnaires to the researchers and were enthusiastic to see the results when the research is completed.

Most students in this study had common undesirable effects related to the nose and eyes which are in agreement with the data reported by other studies [17, 19, 23]. Respiratory and GIT tract related symptoms were also observed among students where respiratory distress, cough and sore throat were at high prevalence. This finding was similar to that reported by previous studies [16, 17, 19]. Moreover, about half of students complained of low assimilation after they exposed to formaldehyde which might be due to the high prevalence of unusual tiredness, headache and dizziness documented in this study. This low assimilation result was also reported previously by Onyije and Avwioro [17] and is worth to be considered by the educational system as it may affect the student's assimilation and reduce their learning progress.

Some factors including smoking, gender, wearing glasses, masks and gloves, revealed different kinds of associations with formaldehyde exposure. Smoker students, with different smoking status, were affected by formaldehyde more than non smokers. Unexpectedly, students who ceased smoking before conducting this survey suffered from some unpleasant effects more than the students who were continued smokers. Smoking is considered as a risk factor for disturbances in the GIT including peptic ulcer, gastrointestinal motility and different types of carcinoma [24, 25]. This effect was related to that cigarette's smokes contain many toxic and carcinogenic agents including formaldehyde [26, 27]. This finding may explain why the male students in the current study suffered from GIT disturbances more than the females as all of the female students in this study, and most women in Libya in general, are none smokers because of the Libyan culture traditions in which smoking is not acceptable habit

for women and is enclosed only in the man community. Interestingly, although the laboratory sessions are usually performed just after the lunch time, about 8(14%) of female students usually felt hungry. This observation was similar to a finding reported by Pietrzyk et al showed that 23% of the study participants had an increased appetite during gross anatomy dissection. This observation may needs more investigation to understand how formaldehyde would affect the appetite of those who exposed to it in such places.

In this study we evaluated the effect of using some protective equipment in the anatomy dissection laboratory such as masks and gloves. Students who do not wear medical masks were adversely affected by the exposure to formaldehyde and exhibited certain clinical symptoms such as mouth dryness, respiratory distress and prolonged sleeping time. It seems that wearing masks may reduce the harm effects caused by formaldehyde which is in agreement with another study that has recommended wearing active carbon masks may reduce formaldehyde vapor air concentration [28]. Although wearing gloves in this study was significantly related to headache ($P= 0.017$) and temporarily loss of smelling and vision ($P=0.026$) compared with students who do not wear gloves, no significant correlation between the participants were observed in regarding to skin symptoms as the commercially available medical gloves in Libya are mostly from the latex powdered type which is well known to be responsible for sensitization [29-31]. Interestingly, students who wear glasses complained of excessive lacrimation, redness, itching or sore eyes. The possible reason of these harmful effects might be due to accumulation of the formaldehyde vapors under the glasses which can causes serious eye injuries or blindness [5].

All of the anatomy staff members complained of nasal itching, burning and congestion, eyes burning and redness, excessive lacrimation, cough and respiratory distress. This 100% response may be due to their longer and daily exposure to formaldehyde compared with students. Wei and colleagues reported that subjective symptoms during the anatomy dissection course were related to the period spent in the anatomy dissection hall and they suggested shortening the time of each anatomy sessions and reducing the number of cadaver tables may help to minimize the adverse formaldehyde effects [32].

In conclusion, despite formaldehyde is still a popular choice of tissue fixation because of its effectiveness and low cost, the current study which is conducted

for the first time in the Libyan universities, supports the literature reports and revealed that the use of formaldehyde to preserve animal cadavers has many adverse health effects on students as well as staff members. To minimize these adverse effects, firstly, students should be provided with safety instructions to raise their awareness to the health hazards during the gross anatomy sessions, importantly wearing masks but not wearing glasses during these sessions. Secondly, it is necessary to follow more precautionary measures including periodical risk assessment to evaluate the extent of risk on students and staff's health. Thirdly, installation of dissection tables equipped with local exhaust ventilation system could reduce the concentration of formaldehyde harmful vapors in the gross anatomy laboratory to the maximum level as suggested by Yamato et al [33] and Kikuta et al [34]. Finally, Switching to alternative preservative methods, such as freezing, might be a safer way of tissues preservation than using formaldehyde.

6. Acknowledgments

The authors thank all students and gross anatomy dissection staff members at university of Tripoli for their contribution and participation in this study.

7. References

- [1]. Dixit D, Athavia PD, Pathak HM. Role of standardized embalming fluid in reducing the toxic effects of formalaldehyde. *Indian Journal of Forensic Medicine and Toxicology*. 2008;2(1):1-6.
- [2]. Bernstein RS, Stayner LT, Elliott LJ, Kimbrough R, Falk H, Blade L. Inhalation exposure to formaldehyde: an overview of its toxicology, epidemiology, monitoring, and control. *Am Ind Hyg Assoc J*. 1984;45(11):778-85.
- [3]. Coleman R, Kogan I. An improved low-formaldehyde embalming fluid to preserve cadavers for anatomy teaching. *J Anat*. 1998;192 (Pt 3):443-6.
- [4]. Patil GV, Shishirkumar, Thejeshwari, D A, Sharif J, C.Sheshgiri, et al. Physical reactions of Formalin used as cadaver preservative on First year Medical students. *Journal of Evidence Based Medicine and Healthcare*. 2014;1(5):279-83.
- [5]. Raja DS, Sultana B. Potential health hazards for students exposed to formaldehyde in the gross anatomy laboratory. *J Environ Health*. 2012;74(6):36-40.
- [6]. Wantke F, Focke M, Hemmer W, Bracun R, Wolf-Abdolvahab S, Gotz M, et al. Exposure to formaldehyde and phenol during an anatomy dissecting course: sensitizing potency of formaldehyde in medical students. *Allergy*. 2000;55(1):84-7.
- [7]. Flyvholm MA, Menne T. Allergic contact dermatitis from formaldehyde. A case study focussing on sources of formaldehyde exposure. *Contact Dermatitis*. 1992;27(1):27-36.
- [8]. Yang X, Zhang YP, Chen D, Chen WG, Wang R. Eye irritation caused by formaldehyde as an indoor air pollution--a controlled human exposure experiment. *Biomed Environ Sci*. 2001;14(3):229-36.
- [9]. Pandey CK, Agarwal A, Baronia A, Singh N. Toxicity of ingested formalin and its management. *Hum Exp Toxicol*. 2000;19(6):360-6.
- [10]. MacAllister SL, Choi J, Dedina L, O'Brien PJ. Metabolic mechanisms of methanol/formaldehyde in isolated rat hepatocytes: carbonyl-metabolizing enzymes versus oxidative stress. *Chem Biol Interact*. 2011;191(1-3):308-14.
- [11]. Mizuki M, Tsuda T. [Relationship between atopic factors and physical symptoms induced by gaseous formaldehyde exposure during an anatomy dissection course]. *Alerugi*. 2001;50(1):21-8.
- [12]. Gurbuz N, Coskun ZK, Liman FA, Anil A, Turgut HB. The Evaluation of Formaldehyde Exposure in the Anatomy Laboratories and the Preventive Measures. *GMJ*. 2016;27:98-103.
- [13]. Lorenzoni DC, Pinheiro LP, Nascimento HS, Menegardo CS, Silva RG, Bautz WG, et al. Could formaldehyde induce mutagenic and cytotoxic effects in buccal epithelial cells during anatomy classes? *Med Oral Patol Oral Cir Bucal*. 2017;22(1):e58-e63.
- [14]. Koppel C, Baudisch H, Schneider V, Ibe K. Suicidal ingestion of formalin with fatal complications. *Intensive Care Med*. 1990;16(3):212-4.
- [15]. Chia SE, Ong CN, Foo SC, Lee HP. Medical students' exposure to formaldehyde in a gross anatomy dissection laboratory. *J Am Coll Health*. 1992;41(3):115-9.
- [16]. Elokda E, KM AE, H S. Comparative Study Of Risk Assessment Of Formaldehyde Exposure Among Students In Public And Private Faculties Of Medicine In Egypt. *Egyptian Journal Of Occupational Medicine*. 2009;33(2):143-54.
- [17]. Onyije FM, Avwioro OG. Excruciating effect of formaldehyde exposure to students in gross anatomy dissection laboratory. *Int J Occup Environ Med*. 2012;3(2):92-5.
- [18]. Koirala S, Shah S, Khanal L, Pokhrel C, Poudel D. Effect of Formalin among the medical and dental students attending regular laboratory session in dissecting hall, in Department of Human

- Anatomy, in B.P. Koirala Institute of Health Sciences. Eur J Forensic Sci. 2015;2(2):1-4.
- [19]. Pietrzyk Ł, Torres A, Denisow-Pietrzyk M, Maciejewski R, Torres K. Formaldehyde-related clinical symptoms reported by medical students during gross anatomy cadaver dissection. *Przegl Dermatol* 2016;103:273–80.
- [20]. Nisa G, Shah BA, Shahdad S, Jan N, Samoon S, Ahmad S. Acute Toxic Effects of Formalin on First Year MBBS Students during Dissection In Gross Anatomy Laboratory. *Journal of Dental and Medical Sciences (IOSR-JDMS)*. 2016;15(8):56-9.
- [21]. Coleman R. Reducing the levels of formaldehyde exposure in gross anatomy laboratories. *Anat Rec*. 1995;243(4):531-3.
- [22]. Mirabelli MC, Holt SM, Cope JM. Anatomy laboratory instruction and occupational exposure to formaldehyde. *Occup Environ Med*. 2011;68(5):375-8.
- [23]. Hisamitsu M, Okamoto Y, Chazono H, Yonekura S, Sakurai D, Horiguchi S, et al. The influence of environmental exposure to formaldehyde in nasal mucosa of medical students during cadaver dissection. *Allergol Int*. 2011;60(3):373-9.
- [24]. Bennett JR. Smoking and the gastrointestinal tract. *Gut*. 1972;13(8):658-65.
- [25]. Johnsen R, Forde OH, Straume B, Burhol PG. Aetiology of peptic ulcer: a prospective population study in Norway. *J Epidemiol Community Health*. 1994;48(2):156-60.
- [26]. Godish T. Formaldehyde exposures from tobacco smoke: a review. *Am J Public Health*. 1989;79(8):1044-5.
- [27]. Hoffmann D, Hoffmann I, El-Bayoumy K. The less harmful cigarette: a controversial issue. a tribute to Ernst L. Wynder. *Chem Res Toxicol*. 2001;14(7):767-90.
- [28]. Roy B, Pugazhandhi B, Banerjee I, Sathian B, Khan I, Mondal M, et al. Ophthalmological, ENT complications in dissection lab sharing experiences of medical students from Nepal. *NEURONS*. 2014;1(1):16-22.
- [29]. Arellano R, Bradley J, Sussman G. Prevalence of latex sensitization among hospital physicians occupationally exposed to latex gloves. *Anesthesiology*. 1992;77(5):905-8.
- [30]. Grzybowski M, Ownby DR, Peyser PA, Johnson CC, Schork MA. The prevalence of anti-latex IgE antibodies among registered nurses. *J Allergy Clin Immunol*. 1996;98(3):535-44.
- [31]. Levy D, Allouache S, Chabane MH, Leynadier F, Burney P. Powder-free protein-poor natural rubber latex gloves and latex sensitization. *Jama*. 1999;281(11):988.
- [32]. Wei CN, Harada K, Ohmori S, Wei QJ, Minamoto K, Ueda A. Subjective symptoms of medical students exposed to formaldehyde during a gross anatomy dissection course. *Int J Immunopathol Pharmacol*. 2007;20(2 Suppl 2):23-5.
- [33]. Yamato H, Nakashima T, Kikuta A, Kunugita N, Arashidani K, Nagafuchi Y, et al. A novel local ventilation system to reduce the levels of formaldehyde exposure during a gross anatomy dissection course and its evaluation using real-time monitoring. *J Occup Health*. 2005;47(5):450-3.
- [34]. Kikuta A, Yamato H, Kunugita N, Nakashima T, Hayashi H. [Reducing the levels of formaldehyde exposure during a gross anatomy dissection course with a local ventilation system]. *Kaibogaku Zasshi*. 2010;85(1):17-27.